

## Review

## Recent advances in neuroanatomy: the myotome update

Masahiro Sonoo 

Department of Neurology,  
Teikyo University School of  
Medicine, Itabashi-ku, Tokyo,  
Japan

**Correspondence to**

Dr Masahiro Sonoo, Department  
of Neurology, Teikyo University  
School of Medicine, Itabashi-  
ku 1738605, Tokyo, Japan;  
sonoom@fk2.so-net.ne.jp

Received 19 October 2022  
Accepted 10 January 2023  
Published Online First 18  
January 2023

**ABSTRACT**

The myotome of a muscle is the basis for diagnosing spinal and peripheral nerve disorders. Despite its critical importance in clinical neurology, myotome charts presented in many textbooks, surprisingly, show non-negligible discordances with each other. Many authors do not even clearly state the bases of their charts. Studies that have presented with raw data regarding myotome identification are rather rare. A classic study in the 19th century that pursued the nerve course in cadavers still has a substantial influence on existing charts, despite its definite limitations. Other scarce studies in humans include identification by root stimulation during surgery, clinical observations in root avulsion or spinal cord injury and clinical and electromyographical investigations in patients with single radiculopathies or certain plexopathies. A few recent studies have proposed new theories regarding the myotomes of some muscles. T1 innervation of the median intrinsic hand muscles is a typical example. We have added a number of new findings, such as T1 innervation of the forearm flexor muscles innervated by the median nerve except the pronator teres and flexor carpi radialis, C5 innervation of the brachioradialis, and two C6 indicator muscles, pronator teres and extensor carpi radialis brevis. Increased accuracy of the myotome charts will improve the localisation in neurology.

**INTRODUCTION: CLINICAL ROLES OF MYOTOMES**

The myotomes of muscles play an important role in clinical practice. First, they can be the basis for diagnosing patients presenting with weakness or atrophy. Motor involvement that coincides with myotomal distribution typically suggests radiculopathy<sup>1,2</sup> or cervical spondylotic amyotrophy (CSA) that is common in Japan and other Asian countries,<sup>3,4</sup> and not plexopathy, peripheral neuropathy or systemic disorders such as amyotrophic lateral sclerosis (ALS). Another role of the myotome is its help to treatment. Identification of the involved root or impaired spinal level based on the knowledge of the myotome and dermatome will guide the surgeon regarding the root or vertebra to be explored.

Because of such clinical significance, myotome charts are presented in many textbooks. However, there are non-negligible discordances among them, which can be a serious problem considering the critical clinical roles mentioned above. In this article, I would like to review how the myotomes have been identified by past studies, the bases of

existing myotome charts and also to cover some recent updates. I will mainly discuss upper-limb myotomes, but briefly mention those of the lower-limb in the final section. Similar reviews have been published in Japanese.<sup>5–7</sup>

**BASES OF EXISTING CHARTS**

The bases of myotome charts in textbooks or articles can be classified as follows:

- Based on an original study investigating the myotome.
- Explicitly stating that the chart is based on an existing one by other author(s).
- Based on the researchers' own experiences, often modifying existing charts, although the experiences themselves are not explicitly explained.
- No mention of the basis of the chart.

Many charts are classified as category C or D, indicating that their bases are not explicitly stated. Those in category A are somewhat rare and can be further classified as follows according to the method to identify the myotomes:

- Anatomical dissection.
- Intraoperative stimulation of the nerve root.
- Manual muscle testing (MMT) or EMG findings in clinical cases.

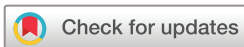These are methodologies applicable to humans. In animals, more invasive methods are possible and there are classical studies that have investigated myotomes in dogs or primates. Although results in primates may be of some reference,<sup>8</sup> we should apply such results to humans with caution.

**RAW DATA OF MYOTOME IDENTIFICATION AND THEIR LIMITATIONS****Anatomical dissection**

In the late 19th century, Herringham<sup>9</sup> pursued the nerve course in cadavers of fetuses, infants and adults and reported myotomes of upper-limb muscles. This method has obvious limitations however.<sup>10</sup> First, muscular and cutaneous branches may be confused. Second, accurate pursuit of the nerve course through the brachial plexus may be difficult. Lastly, when multiple roots contribute to a certain nerve trunk innervating multiple muscles, the one-for-one identification must be very difficult. Nonetheless, Herringham's identification seems to have substantially influenced existing charts, as later discussed.

**Intraoperative stimulation**

Several authors have investigated myotomes by means of root stimulation during spinal surgery.<sup>11–17</sup>



© Author(s) (or their employer(s)) 2023. No commercial re-use. See rights and permissions. Published by BMJ.

**To cite:** Sonoo M. *J Neurol Neurosurg Psychiatry* 2023;**94**:643–648.

This may be considered a reliable method, although spread of the electrical stimulation to adjacent roots may occur. In fact, a recent study has shown surprising results, such as C3 contribution to the biceps brachii,<sup>16</sup> which is difficult to believe. Another limitation would be the confusion with the response from other muscles when the response is monitored just by palpation<sup>12</sup> or by compound muscle action potential.<sup>13 15-17</sup>

**Clinical cases**

Other authors have determined the myotome based on careful observation of patients having a documented lesion. A typical disorder is single-root radiculopathy,<sup>18-24</sup> but transverse myelopathy,<sup>25</sup> meningomyelocele,<sup>10</sup> root avulsion,<sup>26 27</sup> true neurogenic thoracic outlet syndrome (TN-TOS)<sup>23 28</sup> and postmedian sternotomy C8 plexopathy (PS-C8P)<sup>23 28</sup> have also been investigated. This approach is promising, although it may also have pitfalls. Regarding radiculopathy, we should pay attention to how the responsible root was identified. Surgical confirmation associated with postsurgical improvement is used in some studies.<sup>18 20</sup> However, preoperative localisation must have been performed based on clinical symptoms, helped by the knowledge of the myotome (a tautology) and dermatome, and imaging findings. Postsurgical improvement cannot be a gold standard since radiculopathy frequently recovers spontaneously. Localisation using MRI<sup>22-24</sup> may also have limitations due to incomplete specificity.<sup>29-31</sup> Regarding other disorders, the T1 root is predominantly, but not exclusively, involved in TN-TOS.<sup>28</sup> T1 components may also be involved in PS-C8P.<sup>32</sup>

The methods to document abnormality in patients also have inherent limitations. MMT is not free from subjective bias. Some joint motion may be a composite action of several muscles. Furthermore, lesser contribution may be overlooked, especially in chronic cases where reinnervation compensates for the loss of motor units. Needle EMG can sensitively detect denervation in subacute radiculopathy.<sup>30</sup> However, the number of examined

muscles may be limited in retrospective studies analysing routine examinations,<sup>23 24</sup> in which unnecessary painful examinations were avoided.

**COMPARISON OF EXISTING MYOTOME CHARTS**

Figure 1 compares representative myotome charts and studies providing raw data regarding several upper-limb muscles.<sup>1 9 12 18 20 23-25 27 28 33-50</sup> The classification of evidence level has also been given. The A3 category is further subclassified into A3c (clinical=MMT) and A3e (EMG) according to the method of evaluation. We can see that nearly half of the presented charts are categorised as D, that is, no bases are explicitly stated.

It is difficult to know how the authors of a chart categorised as D determined their identification, but careful comparison may reveal their origin. As Brendler discussed,<sup>12</sup> the basis of such conventional myotome charts might be animal studies or the old anatomical study of human dissection (category A1) by Herringham.<sup>9</sup> In this regard, it is interesting to trace the history of the myotome of the abductor pollicis brevis (APB) as an example. Herringham determined the myotome of the APB, ‘superficial thenar muscles’ to be exact, as C6.<sup>9</sup> This is most probably due to confusion between the cutaneous branch to thumb and the thenar muscular branch. However, many earlier charts up to the 1980s seem to have been influenced by Herringham’s identification and ascribed APB to the C6 and C7 myotomes. After 1980, the C8/T1 origin prevailed, and the dominant T1 supply was proposed in the 1990s, as later discussed.<sup>28 51</sup> In this regard, the identification of the myotome of the APB as T1 by Foerster in 1936 is exceptional and noteworthy,<sup>25</sup> although his identification seems to have been forgotten until being rediscovered by the Cleveland Clinic group.<sup>28 51</sup>

Herringham’s chart seems to have influenced later authors in other muscles too. He determined the myotome of the flexor digitorum superficialis (FDS) as C7/8/T1, and this identification

Authors	Ref. no.	Classification	Herringham, 1887	Foerster, 1936	Bing and Haymaker, 1940	Yess et al., 1957	Dejong, 1967	Brendler, 1968	Kendall et al., 1971	Goss, 1973 (Gry)	Danis and Worthington, 1980	Eisen, 1985	Chu-Andrew and Johnson, 1986	Wilbourn and Ambloff, 1988	Ellenberg et al., 1994	Petrow, 1994	Levin et al., 1996	Levin et al., 1998	Wilbourn and Ambloff, 1998	Mayo clinic, 1998	Geiringer, 1999	Dimitru and Zwarts, 2002	Guarantors of Brain, 2010	Preson and Shapiro, 2012	Osipov, 2013	Kimura, 2013	Hilsoe et al., 2014 (Danish)	Chhe et al., 2014	Ball et al., 2017	Funkawa et al., 2021	
Brachioradialis	9	A1																													
Extensor Carpi Radialis	25	A3c																													
Pronator Teres	33	D																													
Flexor Pollicis Longus	18	A3c																													
Flexor Digitorum Superficialis	34	D																													
Abductor Pollicis Brevis	12	A2																													
	35	B																													
	36	D																													
	37	D																													
	38	D																													
	39	C																													
	40	C																													
	41	C																													
	42	D																													
	20	A3e																													
	28	A3e																													
	1	C																													
	43	D																													
	44	C																													
	45	B																													
	46	D																													
	47	D																													
	48	D																													
	49	D																													
	50	D																													
	23	A3ce																													
	27	A3c																													
	24	A3ce																													

**Figure 1** Comparison of myotomal identification (upper-limb). Six (or seven) muscles, brachioradialis, extensor carpi radialis longus/brevis, pronator teres, flexor pollicis longus, flexor digitorum superficialis and abductor pollicis brevis, were compared for existing myotome charts and studies presenting the raw data investigating myotomes. The latter are marked in red. Ref. no. indicates the reference number in this article. Classification means the evidence level explained in the text. \*1 superficial thenar, \*2 thenar. ECRB, extensor carpi radialis brevis; ECRL, extensor carpi radialis longus.

was adopted by most subsequent charts without criticism. As later mentioned, we first argued that the FDS is mainly innervated by T1.<sup>23</sup> Other examples include C5/6/7 for the serratus anterior and C5/6 for the brachialis. No new evidence has been presented for these muscles so far except that by Foerster who reached a similar conclusion,<sup>25</sup> and the identification by Herringham has been adopted for all following charts if the relevant muscles are listed.

### MULTIPLE INNERVATION AND ANATOMICAL VARIATIONS

In the charts I have presented (shown later), I tried to specify a single dominant root in as many cases as possible. Some of the existing charts evenly list multiple contributing roots. C6/7/8 for the triceps brachii,<sup>48 50</sup> and L4/5/S1 for the tibialis anterior (TA)<sup>34 36–38 50</sup> are such examples. Multiple innervations for a given muscle or considerable interindividual variations<sup>52</sup> have been assumed to be the reasons that warrant such guarded descriptions. It is surprising, however, that even in an article arguing the overlap of innervation based on intraoperative root stimulations, single innervation was found, for example, in 35% of subjects for the TA muscle (L5, 27.5%; S1, 5%; L4, 2.5%).<sup>17</sup> Complete foot drop due to evident S1 radiculopathy with no recovery<sup>53</sup> would be another evidence that TA can be solely innervated by S1 in some case, although these authors interpreted this as the evidence of the overlapped innervation. If this is the case, however, supply from roots other than S1, for example, L5, would have caused only partial paresis or prompt recovery due to reinnervation. These results indicate that the height within the spinal cord of the anterior horn cell column innervating the TA is often less than one spinal segment. Sharrard stressed that the cells of the motor columns supplying individual muscles retain a constant mutual relationship within the spinal cord.<sup>10</sup> In this regard, random and unpredictable variations may not exist but the main variation is just a prefixed or postfixed situation.<sup>10</sup> Apparent 'multiple innervation' may just be the result of prefixed or postfixed variations.

Considering all above, listing multiple roots for a given muscle evenly without accent is not only far from the actual fact, but also devalues the chart when applied to clinical practice. Giving the range of possible nerve supply may be useful for evaluating patients with extreme prefixed or postfixed innervations, but it has been reported that a prefixed or postfixed anomaly was rather rare at least for the brachial plexus.<sup>54</sup>

### RECENT UPDATES

#### Myotomes of the intrinsic hand muscles

Studies by the researchers at the Cleveland Clinic provided a new insight in this field.<sup>40 51 55</sup> They found that patients presenting with tingling in ulnar fingers after thoracic surgery showed greater involvements of the motor conduction study (MCS) and the sensory conduction study (SCS) of the ulnar nerve than the MCS of the median nerve and SCS of the medial antebrachial cutaneous nerve (MAC), and named the condition postmedian sternotomy C8 plexopathy (PS-C8P). In contrast, patients with TN-TOS presented with greater involvement of the median MCS and MAC-SCS. Based on these results, they concluded that the median intrinsic hand muscles, typically APB, are dominantly innervated by T1, whereas the ulnar intrinsic hand muscles, that is, the abductor digiti minimi (ADM) and first dorsal interosseous (FDI) are dominantly innervated by C8.<sup>28 51 55</sup> T1 innervation of the APB was further confirmed by the predominant impairment of this muscle following rare T1 radiculopathy.<sup>56 57</sup>

#### Myotomes of the forearm flexor muscles

We investigated MMT and EMG findings of patients with MRI-confirmed C8 radiculopathy, PS-C8P and TN-TOS.<sup>23</sup> The results showed that the FDS, flexor digitorum profundus of the index finger (FDP1) and flexor pollicis longus (FPL) were mainly innervated by T1, whereas the flexor carpi ulnaris (FCU) and flexor digitorum profundus of the little finger (FDP4) were mainly innervated by C8. Accordingly, the relationship of median-T1 and ulnar-C8 was no less evident in the forearm flexor muscles (excluding the pronator teres and flexor carpi radialis) than in the intrinsic hand muscles.

There are a few more points to be noticed in this study. First, the FPL has been conventionally considered to be a typical C8 muscle,<sup>1 12 20 41 42 44 46 47 49</sup> but it was actually a predominantly T1 muscle, although the contribution of C8 may be larger to the FPL than to the APB or FDS. Second, the dissociation between FDP1 and FDP4 (figure 2) might have been conventionally considered to be a sign of peripheral nerve involvement. However, it is now evident that such a dissociation can be caused by a segmental lesion. In particular, the distal type of CSA, an important ALS mimic in Japan, mainly affects the C8 segment,<sup>58</sup> and therefore FDP4 is usually weaker than FDP1 in this disorder. We have described split finger, that is, weaker FDP1 than FDP4, as a characteristic feature of ALS.<sup>59</sup> The pattern is opposite between distal CSA and ALS, and may be useful in differentiating the two disorders.

T1-innervated muscles have also been identified by observations of patients with root avulsion showing a C5–C8 lesion sparing T1.<sup>26 27 60</sup> These studies commonly suggested that the FDS, FDP1, FPL, APB, pronator quadratus and palmaris longus were mainly supplied by T1, in accordance with our results. The partial contribution of T1 for the ADM and FDI was also suggested by these studies, which also coincides with our identification.<sup>23</sup>

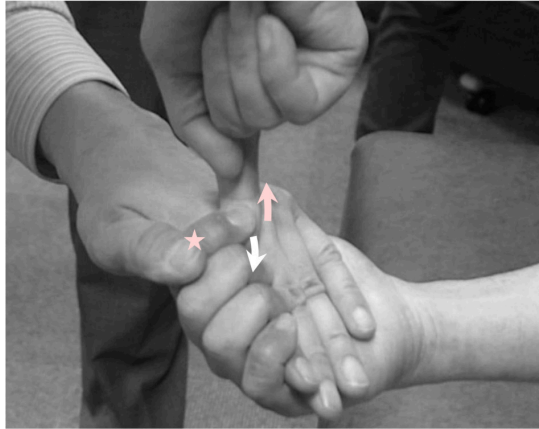
The FCU is innervated by the ulnar nerve, and hence is considered to be derived from C8/T1 root—lower trunk—medial cord. Pyun *et al*<sup>61</sup> documented C7 contribution to FCU using EMG in half of patients with C7 radiculopathy. They also conducted a cadaver study and found the branches from the lateral cord to the ulnar nerve or to the medial cord in 13% of arms.<sup>61</sup> We also observed C7 contribution to the FCU in the study mentioned in the next section.<sup>24</sup>

#### C5/6/7 myotomes

We investigated MMT and EMG findings of patients having a single-root lesion confirmed by MRI at the C5/6/7 level.<sup>24</sup> The results were consistent with most of the past literature for some muscles, though with some disagreements. The latter includes C5 dominant innervation for the brachioradialis (BR), C5/6 for the extensor carpi radialis longus (ECRL), C6>C7 for the extensor carpi radialis brevis (ECRB) and C6>C7 for the pronator teres (PT).

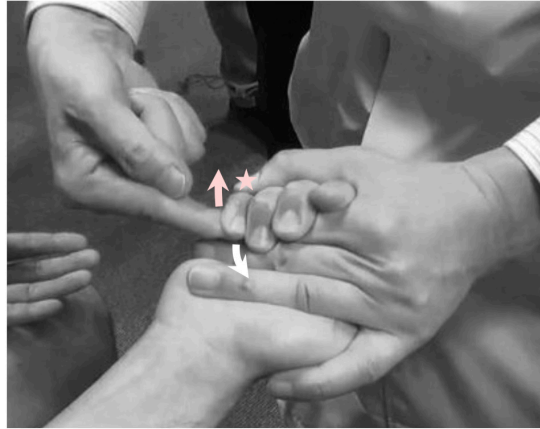For the BR, most charts ascribed its myotome to C6 or equally to C5 and C6 (figure 1). The only past authors who described C5-dominant contribution to the BR<sup>12 18</sup> presented with raw data of identification. A few authors ascribed the PT mainly to C6,<sup>9 12 39 41</sup> although most others equally to C6 and C7, or dominantly to C7. However, the role of the PT in differentiating between a pure C5 lesion and (C5 plus) C6 lesion has been argued by some authors.<sup>20 62</sup> Although the more rostral myotome of the ECRL compared with the ECRB has been postulated by some of the past authors,<sup>25 38 48–50</sup> we are the first to identify the

FDP1



median N. T1

FDP4



ulnar N. C8

**Figure 2** The methods of manual muscle testing of FDP1 and FDP4. White arrow: the direction in which the subject exerts the force. pink arrow: the direction in which the examiner resists the force of the subject. pink star: the fixation point. FDP1, flexor digitorum profundus of the index finger; FDP4, flexor digitorum profundus of the little finger; N, nerve (reprinted and changed with permission from Sonoo, 2018<sup>66</sup>).

ECRL as C5/6 and the ECRB as C6>7.<sup>24</sup> Past authors postulated more caudal localisations.

Levin *et al*<sup>20</sup> extensively studied upper-limb myotomes based on EMG findings of patients with single-root radiculopathy and concluded that they could not find any specific EMG pattern for C6 radiculopathy. In contrast, we identified two C6-dominant muscles, the PT and ECRB.<sup>24</sup> Patients with C6 radiculopathy also presented with a specific MMT pattern, mild weakness only in the PT and wrist extensor. Levin *et al* found denervation in the TB in more than half of patients with C6 radiculopathy.<sup>20</sup> We

cannot judge this point because we did not perform EMG of the TB in patients with C6 radiculopathy, but normal force of this muscle in such patients suggests that contribution of C6 to the TB would be minor, if any.

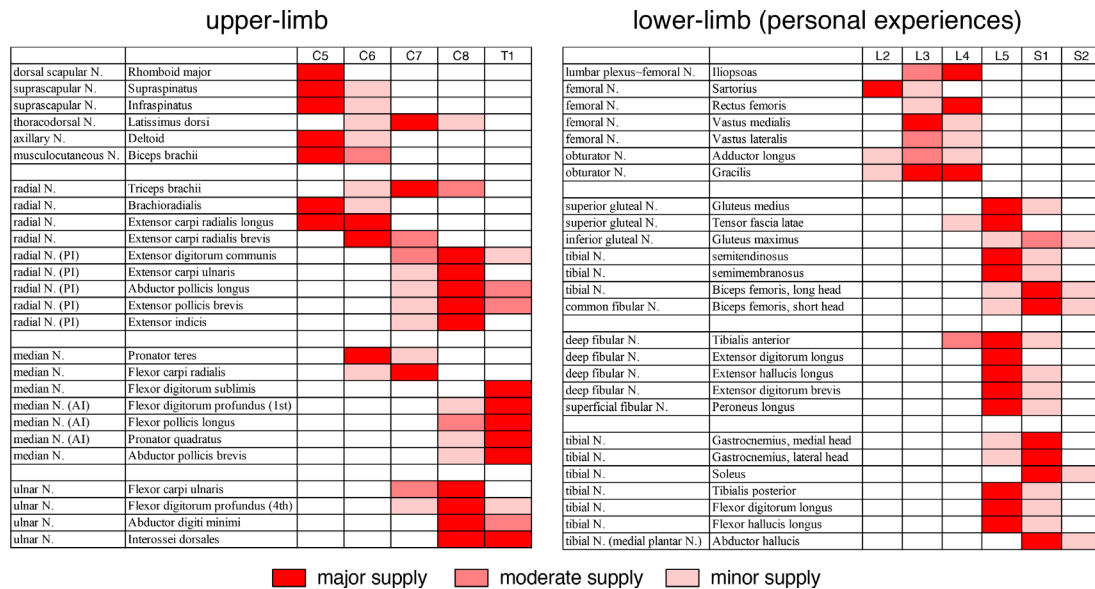
LOWER-LIMB MYOTOME

Figure 3 compares existing myotome charts and past studies regarding several lower-limb muscles.<sup>1 10 11 13–15 17 19 21 25 33–39 42–50</sup> We have not published any articles regarding lower-limb myotomes,

Authors	Ref. no.	Classification	T12	L1	L2	L3	L4	L5	S1	S2	S3
Sonoo, 2023 (present article)		C									
Georgoulis and Sindou (2020)	17	A2									
Hilser <i>et al.</i> , 2014 (Daniels)	50	D									
Kimura, 2013	49	D									
Campbell, 2013 (Deyong)	48	D									
Pesson and Shapiro, 2012	47	D									
Guarinos of Brach, 2010	46	D									
Iso <i>et al.</i> , 2003	21	A3e									
Dimitru and Zwarts, 2002	45	B									
Geiringer, 1999	44	C									
Wilbourn and Amisoff, 1998	43	C									
Mayo clinic, 1998	42	D									
Petro, 1994	41	D									
Ligon <i>et al.</i> , 1992	15	A2									
Phillips and Park, 1991	14	A2									
Chu-Andrews and Johnson, 1986	39	C									
Eisen, 1985	38	D									
Young <i>et al.</i> , 1983	13	A2									
Johnson and Fletcher, 1981	19	A3e									
Daniels and Worthingham, 1980	37	D									
Goss, 1973 (Gray)	36	D									
Kendall <i>et al.</i> , 1971	35	B									
DeJong, 1967	34	D									
Thiger, 1965	11	A2									
Sheward, 1964	10	A3c									
Bing and Haymaker, 1940	33	D									
Foerster, 1936	25	A3c									

**Figure 3** Comparison of myotomal identification (lower-limb). Six muscles, iliopsoas, rectus femoris, vastus medialis, biceps femoris (short head), tibialis anterior and flexor hallucis longus, were compared for existing myotome charts and studies presenting the raw data investigating myotomes. The latter are marked in red. Ref. no. indicates the reference number in this article. Classification means the evidence level explained in the text.





**Figure 4** Myotome charts of the upper-limb (left) and the lower-limb (right) of this author. Note that the evidence levels are quite different between the two charts: category A for many muscles in the upper-limb chart, and category C for the lower-limb chart. Major supply: innervated in all or most subjects (when raw data exists: same for the followings). Moderate supply: innervated in around half of subjects. Minor supply: innervated in small number of subjects. AI, anterior interosseous nerve; N., nerve; PI, posterior interosseous nerve.

except for a meeting presentation that investigated a small number of patients with L3 or L4 monoradiculopathy.<sup>63</sup>

Whether the myotome of the TA is L4 or L5 has been controversial. Raw data supporting L4 origin<sup>10 11 14 25</sup> and those supporting L5 origin<sup>13 15 17 20</sup> both exist. It is evident that L5 radiculopathy often causes foot drop, but it is generally accepted that the myotome of the TA is slightly more rostral than other L5 muscles including toe extensors. As already discussed, there may be normal variations in the sense of prefixed or postfixed anomalies.

S1 dominant innervation for the short head of the biceps femoris (BFSH) supported by the raw data of Tsao *et al*<sup>20</sup> is worth mentioning. In the diagnosis of foot drop, needle EMG of the BFSH is recommended for localisation since this is the only muscle innervated by the fibular nerve proximal to the poplitea.<sup>64 65</sup> The myotome of the BFSH is often considered L5,<sup>64</sup> and abnormal TA with normal BFSH may be interpreted as indicating a lesion in between, that is, at the fibular head. However, foot drop following L5 radiculopathy may spare BFSH that is mainly supplied by S1. To confirm an L5 lesion, the most important key is the examination of non-fibular L5 muscles such as the flexor digitorum longus, flexor hallucis longus, tibialis posterior, semitendinosus, gluteus medius, and tensor fascia latae (figure 4),<sup>64 65</sup> not only by EMG but also by MMT.<sup>66</sup>

## MYOTOME CHARTS OF THIS AUTHOR AND CONCLUSION

Figure 4 lists the present myotomes I use for upper-limb muscles and lower-limb muscles. It should be noted that the evidence levels of the two charts are quite different. The considerable part of the upper-limb chart is based on our published<sup>23 24</sup> studies (category A), complemented by our own unpublished experiences or existing charts for the remaining muscles. In contrast, the lower-limb chart is mostly based on our own experiences<sup>63</sup> complemented by review of existing charts, that is, it should be classified as category C.

As discussed already, every method to determine myotomes has limitations. We should bear in mind that no existing myotome chart is perfect in this regard. Obviously, even our identification

for the upper-limb presented in figure 4 remains an opinion and needs further verification. Despite these limitations, myotomes are very useful in clinical practice, and we should continue efforts to improve them.

**Acknowledgements** I would like to thank main co-authors of our past studies, Dr Takashi Chiba and Dr Yuichi Furukawa (Teikyo University School of Medicine, Tokyo, Japan), Dr Mana Higashihara (Tokyo Metropolitan Geriatric Hospital, Tokyo, Japan) and Dr Akiko Kadoya (National Defense Medical College, Tokorozawa, Japan) for contribution to this article.

**Contributors** MS designed the entire article, wrote and finalised the manuscript.

**Funding** This study was partly supported by Grants-in-Aid for Scientific Research (22K07524) from the Ministry of Education, Science, Sports and Culture of Japan, Health and Labour Sciences Research Grant on Intractable Diseases (Neuroimmunological Diseases) from the Ministry of Health, Labour and Welfare of Japan (20FC1030), and by AMED under Grant Number 19ek0109252h0003.

**Competing interests** None declared.

**Patient consent for publication** Not applicable.

**Ethics approval** Not applicable.

**Provenance and peer review** Not commissioned; externally peer reviewed.

## ORCID iD

Masahiro Sonoo <http://orcid.org/0000-0003-2410-9468>

## REFERENCES

- Wilbourn AJ, Aminoff MJ. AAEM minimonograph 32: the electrodiagnostic examination in patients with radiculopathies. *Muscle Nerve* 1998;21:1612–31. [http://doi.wiley.com/10.1002/\(SICI\)1097-4598\(199812\)21:12<1612::AID-MUS2>3.0.CO;2-0](http://doi.wiley.com/10.1002/(SICI)1097-4598(199812)21:12<1612::AID-MUS2>3.0.CO;2-0).
- So YT, American Association of Electrodiagnostic Medicine. Guidelines in electrodiagnostic medicine. practice parameter for needle electromyographic evaluation of patients with suspected cervical radiculopathy. *Muscle Nerve Suppl* 1999;8:S209–21.
- Takahashi T, Hanakita J, Minami M, *et al*. Cervical spondylotic amyotrophy: case series and review of the literature. *Neurospine* 2019;16:579–88.
- Luo W, Li Y, Xu Q, *et al*. Cervical spondylotic amyotrophy: a systematic review. *Eur Spine J* 2019;28:2293–301.
- Sonoo M, Suzuki M, Araki N, *et al*. Updates of neuroanatomy that are useful for the diagnosis of cervical spine disorders. Annual Review, Neurology; Tokyo: Chugai-Igaku ya.2021:122–9.
- Sonoo M. Update of the myotome. *Spine and Spinal Cord* 2021;34:324–30.

- 7 Sonoo M. Myotome. In: Sonoo M, ed. *Basic neurological symptomatology of spinal cord and neuromuscular disorders*. Tokyo: Miwa-shoten, 2022.
- 8 Ferrier D, Yeo GF. II. The functional relations of the motor roots of the brachial and lumbo-sacral plexuses. *Proc R Soc Lond* 1881;32:12–20.
- 9 Herringham WP. The minute anatomy of the brachial plexus. *Proc R Soc Lond* 1887;41:423–41.
- 10 SHARRARD WJ. The segmental innervation of the lower limb muscles in man. *Ann R Coll Surg Engl* 1964;35:106–22.
- 11 Thage O. The myotomes L2 – S2 in man. *Acta Neurol Scand Suppl* 1965;13 Pt 1:241–3.
- 12 Brendler SJ. The human cervical myotomes: functional anatomy studied at operation. *J Neurosurg* 1968;28:105–11.
- 13 Young A, Getty J, Jackson A, et al. Variations in the pattern of muscle innervation by the L5 and S1 nerve roots. *Spine (Phila Pa 1976)* 1983;8:616–24.
- 14 Phillips LH, Park TS. Electrophysiologic mapping of the segmental anatomy of the muscles of the lower extremity. *Muscle Nerve* 1991;14:1213–8.
- 15 Liguori R, Krarup C, Trojaborg W. Determination of the segmental sensory and motor innervation of the lumbosacral spinal nerves. An electrophysiological study. *Brain* 1992;115 (Pt 3):915–34.
- 16 Schirmer CM, Shils JL, Arle JE, et al. Heuristic map of myotomal innervation in humans using direct intraoperative nerve root stimulation. *J Neurosurg Spine* 2011;15:64–70.
- 17 Georgoulis G, Sindou M. Muscle responses to radicular stimulation during lumbo-sacral dorsal rhizotomy for spastic diplegia: insights to myotome innervation. *Clin Neurophysiol* 2020;131:S1388-2457(20)30064-X:1075–86.
- 18 YOSS RE, CORBIN KB, MACCARTY CS, et al. Significance of symptoms and signs in localization of involved root in cervical disk protrusion. *Neurology* 1957;7:673–83.
- 19 Johnson EW, Fletcher FR. Lumbosacral radiculopathy: review of 100 consecutive cases. *Arch Phys Med Rehabil* 1981;62:321–3.
- 20 Levin KH, Maggiano HJ, Wilbourn AJ. Cervical radiculopathies: comparison of surgical and EMG localization of single-root lesions. *Neurology* 1996;46:1022–5.
- 21 Tsao BE, Levin KH, Bodner RA. Comparison of surgical and electrodiagnostic findings in single root lumbosacral radiculopathies. *Muscle Nerve* 2003;27:60–4.
- 22 Mondelli M, Aretini A, Arrigucci U, et al. Clinical findings and electrodiagnostic testing in 108 consecutive cases of lumbosacral radiculopathy due to herniated disc. *Neurophysiol Clin* 2013;43:S0987-7053(13)00145-7:205–15.
- 23 Chiba T, Konoeda F, Higashihara M, et al. C8 and T1 innervation of forearm muscles. *Clin Neurophysiol* 2015;126:S1388-2457(14)00431-3:837–42.
- 24 Furukawa Y, Miyaji Y, Kadoya A, et al. Determining C5, C6 and C7 myotomes through comparative analyses of clinical, MRI and EMG findings in cervical radiculopathy. *Clin Neurophysiol Pract* 2021;6:88–92.
- 25 Foerster O. Symptomatology der erkrankungen des Rückenmarks und seiner wurzeln. In: Foerster O, Gagel O, Környey ST, eds. *Handbuch der Neurologie* Berlin: Julius Springer, 1936: V. 1–403.
- 26 Nagano A, Ochiai N, Okinaga S, et al. Clinical features and treatment of brachial plexus injury involving C5, C6, C7, C8, roots. *J Jap Soc Surg Hand* 1989;6:422–5.
- 27 Bell SW, Brown MJC, Hems TJ. Refinement of myotome values in the upper limb: evidence from brachial plexus injuries. *Surgeon* 2017;15:S1479-666X(15)00095-5:1–6.
- 28 Levin KH, Wilbourn AJ, Maggiano HJ. Cervical rib and median sternotomy-related brachial plexopathies: a reassessment. *Neurology* 1998;50:1407–13.
- 29 Boden SD, McCowin PR, Davis DO, et al. Abnormal magnetic-resonance scans of the cervical spine in asymptomatic subjects. A prospective investigation. *J Bone Joint Surg Am* 1990;72:1178–84.
- 30 Nardin RA, Patel MR, Gudas TF, et al. Electromyography and magnetic resonance imaging in the evaluation of radiculopathy. *Muscle Nerve* 1999;22:151–5.
- 31 Nakashima H, Yukawa Y, Suda K, et al. Abnormal findings on magnetic resonance images of the cervical spines in 1211 asymptomatic subjects. *Spine (Phila Pa 1976)* 2015;40:392–8.
- 32 Oishi C, Kanbayashi T, Higashihara M, et al. T1 involvement in post-median sternotomy plexopathy. *Muscle Nerve* 2019;60.
- 33 Bing R, Haymaker W. Compendium of regional diagnosis in lesions of the brain and spinal cord. *Southern Medical Journal* 1940;33:558.
- 34 DeJong RN. *The neurologic examination*. 3rd ed. New York: Harper and Row, Medical Division, 1967.
- 35 Kendall HO, Kendall FP, Wadsworth GE. *Muscles: testing and function*. 2nd ed. Baltimore: The Williams and Wilkins Company, 1971.
- 36 Goss GM. *Anatomy of the human body by Henry Gray*. 29th ed. Philadelphia: Lea & Febiger, 1973.
- 37 Daniels L, Worthingham C. *Muscle testing: techniques of manual examination*. 4th ed. Philadelphia: W. B. Saunders, 1980.
- 38 Eisen A. Electrodiagnosis of radiculopathies. *Neurol Clin* 1985;3:495–510.
- 39 Chu-Andrews J, Johnson RJ. *Electrodiagnosis: an anatomical and clinical approach*. Philadelphia: J. B. Lippincott Company, 1986.
- 40 Wilbourn AJ, Aminoff MJ. AAEE minimonograph # 32: the electrophysiologic examination in patients with radiculopathies. *Muscle Nerve* 1988;11:1099–114.
- 41 Ellenberg MR, Honet JC, Treanor WJ. Cervical radiculopathy. *Arch Phys Med Rehabil* 1994;75:342–52.
- 42 Perotto AO. *Anatomical guide for the electromyographer. the limbs and trunk*. 3rd edition. Springfield: Charles C. Thomas, 1994.
- 43 Members of the Mayo Clinic Department of Neurology. *Mayo clinic examinations in neurology*. St Louis: Mosby, 1998.
- 44 Geiringer SR. *Anatomic localization for needle electromyography*. 2nd ed. Philadelphia: Hanley & Belfus Inc, 1999.
- 45 Dumitru D, Zwarts MJ. Radiculopathies. In: Dumitru D, Amato AA, Zwarts MJ, eds. *Electrodiagnostic Medicine*. 2nd ed. Philadelphia: Hanley & Belfus Inc, 2002: 713–76.
- 46 Guarantors of Brain. *Aids to the examination of the peripheral nervous system*. 5th edition. Edinburgh: Saunders Elsevier, 2010.
- 47 Preston DC, Shapiro BE. *Electromyography and neuromuscular disorders: clinical-electrophysiologic correlations*. 3rd ed. London: Elsevier Saunders, 2012.
- 48 Campbell WW. *DeJong's the neurologic examination*. 7th ed. Philadelphia: Wolters Kluwer, 2013.
- 49 Kimura J. *Electrodiagnosis in diseases of nerve and muscle: principles and practice*. 4th ed. New York: Oxford University Press, 2013.
- 50 Hislop HJ, Avers D, Brown M. *Daniels and worthingham's muscle testing: techniques of manual examination and performance testing*. 9th ed. Philadelphia: W. B. Saunders, 2014: 174–6.
- 51 Ferrante MA, Wilbourn AJ. The utility of various sensory nerve conduction responses in assessing brachial plexopathies. *Muscle Nerve* 1995;18:879–89.
- 52 Riew KD. Variations in cervical myotomes and dermatomes. *Spine J* 2019;19:S1529-9430(19)30117-2:1143–5.
- 53 Voermans NC, Koetsveld AC, Zwarts MJ. Segmental overlap: foot drop in S1 radiculopathy. *Acta Neurochir (Wien)* 2006;148:809–13.
- 54 Emamhadi M, Chabok SY, Samini F, et al. Anatomical variations of brachial plexus in adult cadavers; a descriptive study. *Arch Bone Jt Surg* 2016;4:253–8.
- 55 Ferrante MA. Brachial plexopathies: classification, causes, and consequences. *Muscle Nerve* 2004;30:547–68.
- 56 Levin KH. Neurologic manifestations of compressive radiculopathy of the first thoracic root. *Neurology* 1999;53:1149–51.
- 57 Tanaka Y. T1 radiculopathy and its features in symptomatology. *Spine and Spinal Cord* 2017;30:107–10.
- 58 Sonoo M. Cervical spondylotic amyotrophy. *Brain Nerve* 2016;68:509–19.
- 59 Sonoo M, Takahashi K, Hamada Y, et al. Split-finger syndrome in amyotrophic lateral sclerosis. *J Neurol Neurosurg Psychiatry* 2020;91:1235–6.
- 60 Bertelli JA, Ghizoni MF. C5-8 brachial plexus root injury: the " T-1 hand. " *J Neurosurg* 2012;116:409–13.
- 61 Pyun SB, Kang S, Kwon HK. Anatomical and electrophysiological myotomes corresponding to the flexor carpi ulnaris muscle. *J Korean Med Sci* 2010;25:454–7.
- 62 Katirji MB, Agrawal R, Kantra TA. The human cervical myotomes: an anatomical correlation between electromyography and CT/myelography. *Muscle Nerve* 1988;11:1070–3.
- 63 Higashihara M, Hatanaka Y, Ogawa G, et al. L3 and L4 innervation investigated from patients with single-root radiculopathy. *Muscle Nerve* 2016;54:545.
- 64 Wilbourn AJ. AAEE case report # 12: common peroneal mononeuropathy at the fibular head. *Muscle Nerve* 1986;9:825–36.
- 65 Masakado Y, Kawakami M, Suzuki K, et al. Clinical neurophysiology in the diagnosis of peroneal nerve palsy. *Keio J Med* 2008;57:84–9.
- 66 Sonoo M. *Guidebook for MMT and needle EMG*. Tokyo: Chugai Igakusya, 2018.